Pre-Processing of Low-Field Brain MRI

N. F. ISHAK [1], R. LOGESWARAN [2] and W.H. TAN [3]
Faculty of Engineering
Multimedia University
63100 Cyberjaya
MALAYSIA
[1] nur.faiza@mmu.edu.my , [2] loges@ieee.org , [3] twhaw@mmu.edu.my

Abstract: - Low-field Magnetic Resonance Imaging (MRI) is vital in sensitive surgeries to allow real-time imaging in the operation theatre. A major concern in low-field MR images is the poor quality images and low signal-to-noise ratio (SNR) compared to those from conventional MRI scanners. For any successful application to be developed using such images, the image quality has to be improved. In this paper, pre-processing steps are applied to low-field MR brain images. Conceptually, histogram-based analysis shows that most of the low-field MR images consist of three peaks, where the first and second peaks summarizes the background and artifacts of the image, respectively, while the third peak is the region-of-interest (ROI). This paper gives some useful insights of steps that could be taken prior to brain segmentation. Promising results are reported.

Key-Words: - Magnetic resonance imaging (MRI), Image analysis, Histogram analysis, Dynamic thresholding, Normalization, Image enhancement.

1 Introduction

Image processing techniques make it possible to extract meaningful information from medical images. Brain MRI images provide information of brain parts such as white matter, gray matter, cerebrospinal fluid, ventricles, skull and injuries such as bleeding, tumor and skull fracture. Low-field MRI is vital for sensitive surgery to allow real-time imaging in the operation theatre. A truly open low-field system would have a number of advantages including low-cost, reduced MR compatibility demands on instruments to minimize distortion, reduced fringe fields and the relative ease of movement and usage. The main problem with low-field MRI is its low resolution images.

In this paper, we analyze dynamic thresholding in low-field MRI brain images. There has been a lot of research work on pre-processing techniques, image intensity analysis [1-4] and image normalization [5-6] for conventional MR images. However, most of the techniques proposed are not directly applicable to low-field MR images [7]. Hence, an improved method of pre-processing low-field MR images is proposed. The technique allows the structure of the brain to be more clearly visible in the low-field MRI images.

The structure of this paper is as follows. The next section briefly discusses the background of low-field MRI. Section 3 describes the proposed histogram analysis method for low-field MRI images. The results and discussions are given in Section 4, followed by the conclusion in Section 5.

2 Background

Why is low-field MRI more convenient for brain surgery? It is usable in the standard operating room (OR) and hence can update images to reflect the changes in anatomy after opening the skull in neurosurgery [8]. Furthermore, open low-field MRI is preferable to the tunnel-style conventional MRI for claustrophobic patients. Several previous studies have compared conventional MRI (1.5T) versus low-field MRI (0.15T), with most indicating no significant clinical differences in interpretations of low-field versus conventional images [9]. Thus, they are clinically applicable in operations and even routine checkups.

However, since low-field MRI uses low strength electromagnetic fields, noisy low resolution images are produced. In contrast, high-field MRI machines (approximately 7T) are able to produce clear detailed images with almost no noise at all. Considering the above, we are motivated to enhance the low-field images, so that the same conventional and high-field MRI processing techniques and applications could be applied to our pre-processed low-field MRI images.

Fig. 1 shows the differences in conventional and low-field MRI images. Both images were taken from the same patient, for the same slice of the brain. However, the quality is noticeably worse in the low-field image. Not only is the noise level increased, but the orientation and coverage of the brain is affected as well due to the small aperture of the low-field machine. The lower part of the brain is no longer visible and an

artifact is present at the top left (although not very visible in this image, it can hinder automatic processing).

Low-field MRI usually has a black or gray background with an elliptic artifact. The background should be removed as it is not part of the brain. This technique has been used in [10] as one of the pre-processing steps in brain region extraction. In [11], it was expected that a distinct peak in the histogram exist for determining the threshold value for the entire image, such that the image could be properly enhanced.

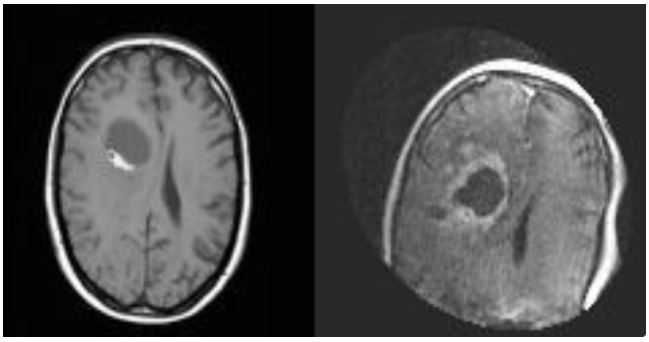

Fig. 1. Conventional MRI (left), low-field MRI (right)

3 Histogram Analysis

As low-field MRI equipments are still quite rare, a database of only 14 patients was available in this work. Each 128x128 pixels image was analyzed, in terms of its intensity histogram. The parts of interest in a typical low-field MRI brain image are labeled in Fig. 2(a), with its histogram given in Fig. 2(b). Any pre-processing undertaken should preserve all the region-of-interest (ROI), which in this case are the labeled areas excluding the artifact and background.

Upon inspection of the histogram, we find that three peaks exist. P1, the first peak, is expected to be the background of the image, while P2 may contain most of the unwanted artifact. As such, the object of interest, which is the brain, should be represented by P3. The fourth peak (P4) exists at intensity 255 in most images. It is present in Fig. 4(b), although not obvious (see in Fig. 5). P4, being the highest intensity, is expected to be parts of the skull and bleeding in the brain.

The objective of image processing is to extract the features of the MRI brain, more specifically the brain tissue, ventricle, skull, and diseased brain areas and abnormalities. Fig. 3 shows the detailed proposed method for pre-processing the image. Three main steps are to be taken, namely, background elimination, artifact elimination and finally image normalization. Elimination of undesirable regions is crucial in order to obtain precise segmentation of the brain.

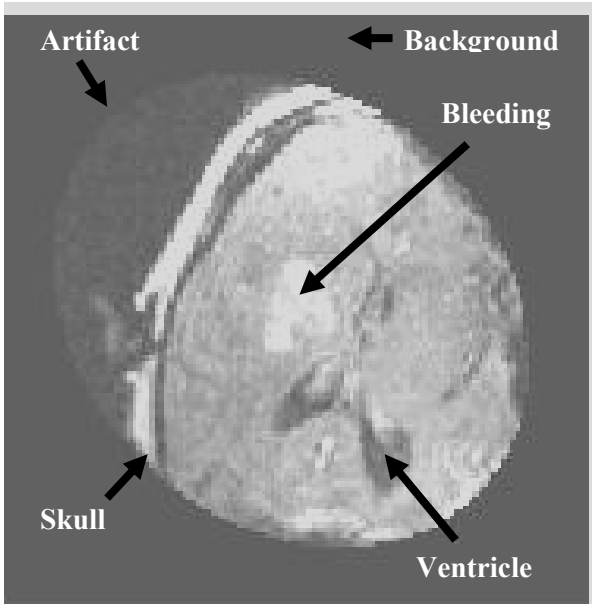

(a) Original image

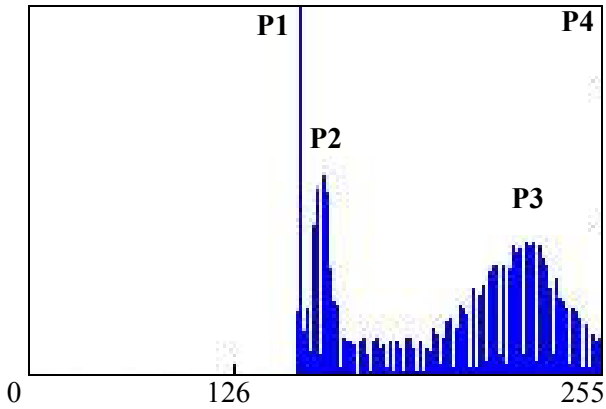

(b) Histogram

Fig. 2. Low-field MRI brain image and histogram

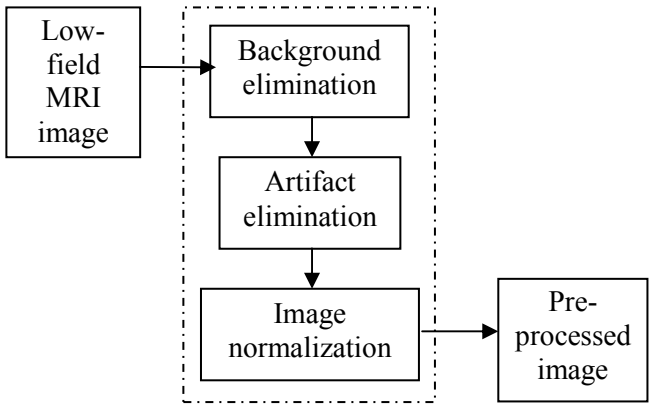

Fig. 3. Flowchart of image pre-processing module

3.1 Histogram Truncation

To examine the above hypothesis, histogram-based pre-processing techniques were applied to the image database. The final image was then normalized to enhance its contrast. Normalization is crucial in order to extract and segment the ROI for future work. This reduces the dynamic range of intensities between images, standardizing them and making them more suitable for subsequent processing.

We begin with the elimination of the first peak (P1), which is expected to be the background. By referring to the result (Fig. 4(a)) of the sample image in Fig. 2(a), we see that the background of the image is removed once the first peak has been eliminated. The region remaining is the elliptical shaped brain with the artifact. This supports the assumption that the first peak consists mostly of the background and its truncation eliminates the background accordingly.

We then proceed with the artifact elimination, i.e. the second peak (P2). By determining the maximum intensity of P2, (1) is used to choose the intensity range in the elimination technique.

$$Threshold,\ T = \frac{\max(\mathrm{P2}) - \min(im)}{p} \qquad (1)$$

where max*(im)* is the maximum intensity value of P2, min*(im)* is minimum intensity of the original image *(im),* and p is the fraction of the slope for each thresholding step. Very small steps (e.g p=1/5) did not produce much differences between the steps. However, large steps (e.g p=1/s2*)* may allow unseen regions to go missing during the process as the step size would be large.

By truncating 1/3 off the second peak of the histogram (i.e. p=1/3), we managed to reduce part of the artifact, as shown in Fig. 4(b). The ROI remains unaffected with this threshold value. Hence, we can proceed with the next 1/3 step elimination from the histogram (i.e. p=2/3). From Fig. 4(c), we see that a significant amount of the artifact has been successfully removed at this step. The human brain can be more clearly identified now as compared to the original image.

Since there are still undesired spots of artifacts in the image, the whole second peak is then removed. Referring to Fig. 4(d), we have now proven that almost all the visible area of the unwanted region has now been successfully removed. The important brain areas such as ventricle, diseased region and brain tissue are unaffected. The processed image is now more like the conventional MR images, where we can differentiate clearly between the brain and the background. The background and artifact has been completely removed and will no longer influence any consequent processing techniques to be applied.

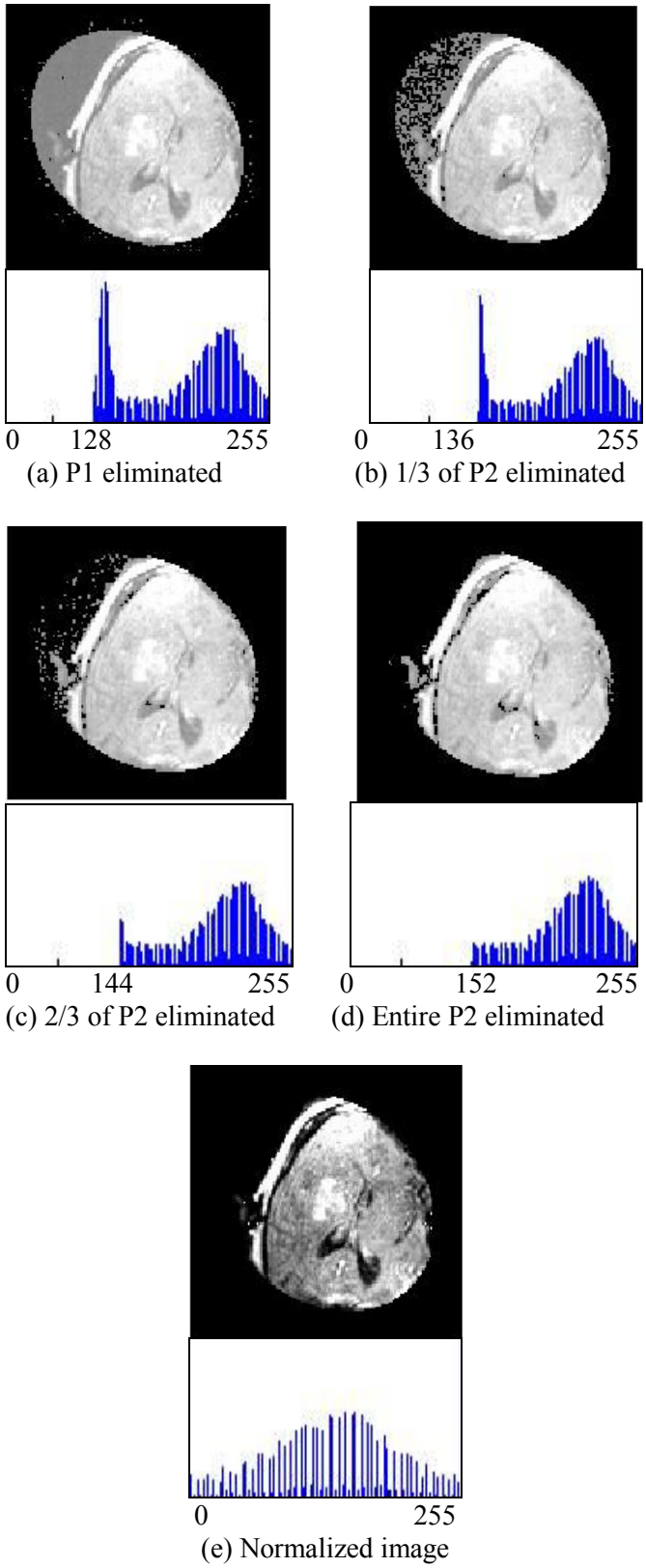

Fig. 4. Histogram truncation and normalization

3.2 Normalization

Truncating the histogram peaks alone is not sufficient. Examining the images available, it was observed that the intensity range of the low-field MRI images are inconsistent (some in the higher ranges whilst others in the lower ranges). Thus, image normalization should be applied to the pre-processed image to standardize the intensity range to 0-255. By stretching the histogram, the image brightness will be more uniform. Some parts of the brain that were not clearly visible would become clearer after normalization. Eq. (2) is used to normalize the image,

$$Normalized,\ N = \frac{Im - T}{\max(Im) - T} \times 255 \qquad (2)$$

where *Im* is the thresholded image, max*(Im)* is the maximum intensity of *Im,* and the multiplication with 255 sets the intensity range between 0-255.

Fig. 4(e) shows the result of the histogram of pre-processed image in Fig. 4(d) stretched from the range 155-255 to 0-255. A clearer image is produced and hence leads towards better identification of the ROI. As an example to illustrate the enhancement, notice that it is difficult to determine the boundaries of the bleed area in Fig. 4(d) (the white area near the middle of the brain). After the image is normalized, the differences can be seen clearly, without the application of any further complicated enhancement techniques. This reduces the time and cost of processing at the subsequent stages.

3.3 Additional Information

An alternative approach after the truncation of P1 is for the resulting histogram to be shifted to the left (see Fig. 5(a)). However, the image appears to be dimmer and the artifact is no longer obvious although it is still present and affects subsequent processing. Nonetheless, the same final result is obtained once the whole of P2 is removed.

In addition, to determine the amount of ROI that has been removed, subtracting the original image with the pre-processed image of Fig. 4(d) shows the differences as in Fig. 5(b). As observed, the whole background was eliminated and only very small parts of the brain area (see the few pixels in the brain area) were affected. This shows that the proposed technique is effective in eliminating unwanted regions while preserving the integrity of the areas of importance (i.e. the brain). The information provided by the subtraction image could be stored and used when further accuracy is required in subsequent processing.

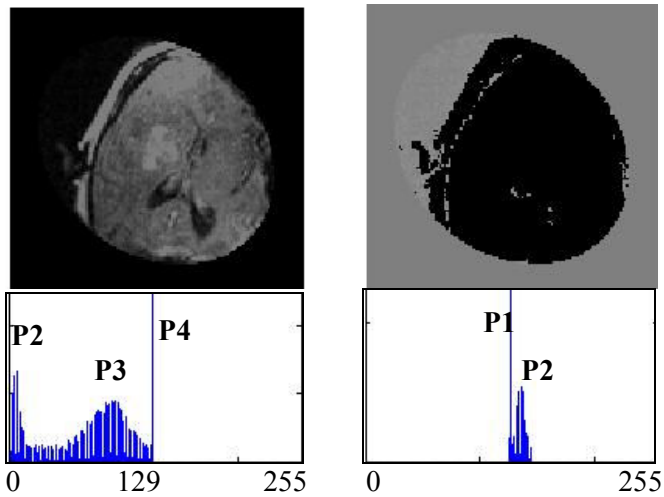

(a) Shifted histogram (b) Subtracted image

Fig. 5. Additional information

4 Results & Discussion

To validate the performance of the proposed pre-processing technique, tests were conducted on the other available images as well. The results achieved by 5 sets of images with different characteristics are given below. The different characteristics were chosen to compare the accuracy and robustness of the technique.

A normal brain image is shown in Fig. 6(a). The separation between ventricle and white matter becomes more obvious after pre-processing. Fig. 6(b) is another example of bleeding in the brain. After image normalization, the brain folds become more visible. The same goes for the bleeding boundaries as well as skull area. In Fig. 6(c), the normalized brain image can be seen clearly compared to the original image. Only one ventricle is present in this image, which may be due to the orientation or abnormalities in the brain. Dissimilarity between skull and brain tissue is obvious and hence, the segmentation process would be easier and more effective than before.

Changes in the brain ventricle volume associated with Alzheimer's disease can be seen in Fig. 6(d). During the brain scan, an external object was placed on the side of the head. This type of additional artifact is not removed using the proposed technique.

The final image is a normal brain scanned as a coronal slice, as shown in Fig. 6(e). The artifact is removed, but certain parts of the brain tissue are affected. The original image taken was dark and the histogram was almost levels distributed. There were no obvious peaks in this low quality image. The performance of the proposed technique is limited in such cases and manual thresholding may be required.

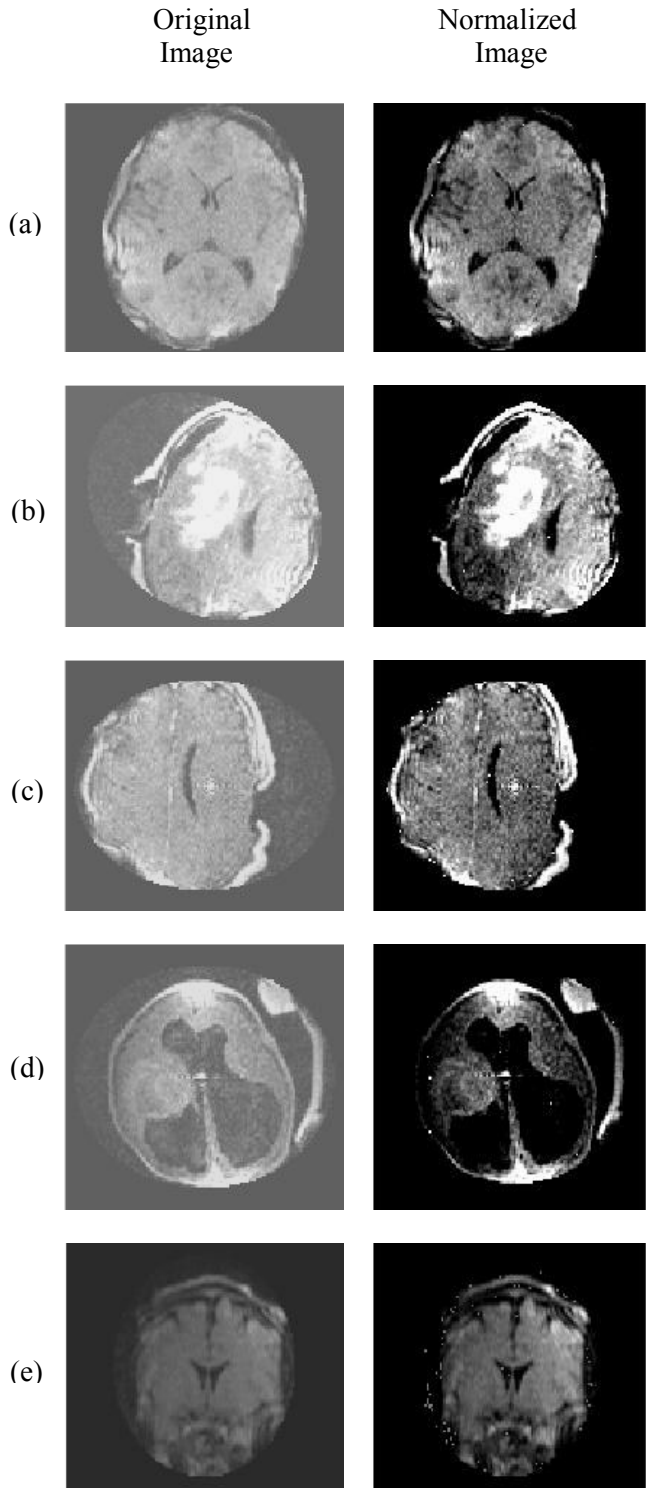

Fig. 6. Results of the proposed pre-processing technique

5 Conclusion

Low-field brain MRI is now being introduced in medical institutions for real-time imaging during surgeries. However, it produces low-resolution images and leads to difficulty in automated segmentation techniques. This work proposes a dynamic thresholding and image normalization technique for enhancement of low-field brain MR images. By truncating and normalizing the histogram, we managed to eliminate the unnecessary background and artifacts in the image. The clarity of the ROI was enhanced effectively while almost no loss of information or image integrity was recorded in the actual brain areas of the processed low-field MRI images.

It is shown in this paper that in the histogram of a typical low-field MRI image, the first peak tends to be the image background and the second peak is the acquisition artifact. We are only concerned with intensity around the third peak, which consists of the main brain object.

In future, further evaluation on special cases of the histogram will be undertaken. The finalized image normalization technique can be used directly for feature extraction and segmentation. However, it is recommended that after pre-processing the image, denoising techniques is applied to remove any residue noise that may still be present in the image, as proposed in [12]. The efficiency, robustness and accuracy of the pre-processing performance would be improved with further detailed analysis.

Acknowledgement

The authors would like to thank the Department of Neurosurgery, Maastricht University Hospital and the Department of Biomedical Engineering, Eindhoven University of Technology (TU/e), for providing the MR images. This project is supported by the Ministry of Science, Technology and Innovation (MOSTI), Malaysia through the Science Fund grant.

References:

[1] U. Vovk, F. Pernu, B. Likar, "Simultaneous correlation of intensity inhomogeneity in multichannel MR images", 27th Annual Conf. Engineering in Medicine and *Biology*, pp. 4290-4293, 2005.

[2] N.I. Weisenfeld, S.K. Warfield, "Normalization of joint image-intensity statistics in MRI using the Kullback-Leibler divergence", *IEEE Symposium on Biomedical Imaging : Nano to Macro*, vol. 1, pp. 101-104, 2004.

[3] A. Madabhushi, J.K. Udupa, "Interplay between intensity standardization and inhomogeneity correction in MR image processing", *IEEE Trans. on Medical Imaging*, vol. 24, pp. 561-576, 2005.

[4] U. Vovk, F. Pernus, B. Likar, "A review of methods for correction of intensity inhomogeneity in MRI", *IEEE Trans. on Medical Imaging*, vol. 26, pp. 405-421, 2007.

[5] Y.L. Liao, N.T. Chiu, C.M. Weng, Y.N. Sun, "Registration and normalization techniques for assessing brain functional images", *Biomedical Engineering Applications, Basis & Communications*, 2003.

[6] J.G. Park, T. Jeong, C. Lee, "Automated brain segmentation algorithm for 3D magnetic resonance brain images", *2nd Intl. Workshop on Soft Computing Applications (SOFA)*, pp. 57-61, 2007.

[7] N.F. Ishak, M.J. Gangeh, and R. Logeswaran, "A preliminary study of high-field MRI image enhancement techniques applied to low-field MR brain images", *4th Intl. Conf. on Biomedical Engineering (BIOMED)*, vol. 21, pp. 482-486, 2008.

[8] P. Hastreiter, C.R. Salama, G. Soza, M. Baeur, et. al, "Strategies for brain shift evaluation", *Medical Image Analysis*, vol. 8, pp. 447-464, 2004.

[9] T. Magee, M. Shapiro, and D. Williams, "Comparison of high-field-strength versus low-field-strength MRI of the shoulder", *American Journal of Roentgenology*, pp. 1211-1215, 2003.

[10] C.S. Yung, S.H. Ki, M.N. Seung, and W.P. Jong, "Threshold estimation for region segmentation of MR image of brain having the partial volume artifact", *5th Intl. Conf. on Signal Processing Proceedings (ICSP)*, vol. 2, pp. 1000-1009, 2000.

[11] M.B. Ahmad, and T.S. Choi, "Local threshold and Boolean function based edge detection", *IEEE Trans. On Consumer Electronics*, vol. 45, pp. 332-333, 1999.

[12] N.F. Ishak, M.J. Gangeh, and R. Logeswaran, "Comparison of denoising techniques applied on low-field MR brain images", *5th Intl. Conf. on Computer Graphics, Imaging and Visualization (CGIV)*, 2008.